
EVIDENCE-BASED MEDICINE

Evidence-based Interventional Pain Medicine
according to Clinical Diagnoses

13. Sacroiliac Joint Pain

Pascal Vanelderden, MD, FIPP^{*,†}; Karolina Szadek, MD[‡]; Steven P. Cohen, MD[§];
Jan De Witte, MD[¶]; Arno Lataster, MSc^{**}; Jacob Patijn, MD, PHD^{††};
Nagy Mekhail, MD PhD, FIPP^{‡‡}; Maarten van Kleef, MD, PhD, FIPP^{††};
Jan Van Zundert, MD, PhD, FIPP^{*,††}

**Department of Anesthesiology, Intensive Care Medicine, Multidisciplinary Pain Centre, Ziekenhuis Oost-Limburg, Genk, Belgium; †Department of Anesthesiology, Pain Therapy and Palliative Care, Radboud University Nijmegen Medical Centre, Nijmegen, The Netherlands;*

*‡Department of Anesthesiology and Pain Management, Vrije Universiteit Amsterdam, Amsterdam, The Netherlands; §Department of Anesthesiology, Johns Hopkins Medical Institutions, Baltimore, Maryland and Walter Reed Army Medical Center, Washington, District of Columbia, U.S.A.; ¶Department of Anesthesiology, Intensive Care Medicine, and Pain Management, OLV-Ziekenhuis, Aalst, Belgium; **Department of Anatomy and Embryology, Maastricht University, Maastricht, The Netherlands; ††Department of Anesthesiology and Pain Management, Maastricht University Medical Centre, Maastricht, The Netherlands; ‡‡Department of Pain Management, Cleveland Clinic, Cleveland, Ohio, U.S.A.*

■ **Abstract:** The sacroiliac joint accounts for approximately 16% to 30% of cases of chronic mechanical low back pain. Pain originating in the sacroiliac joint is predominantly perceived in the gluteal region, although pain is often referred into the lower and upper lumbar region, groin, abdomen, and/ or lower limb(s). Because sacroiliac joint pain is difficult to distinguish from other forms of low back pain based on history, different provocative maneuvers have been advocated. Individually, they have weak predictive value, but combined batteries of tests can help ascertain a diagnosis. Radiological imaging is important to exclude "red flags" but

contributes little in the diagnosis. Diagnostic blocks are the diagnostic gold standard but must be interpreted with caution, because false-positive as well as false-negative results occur frequently. Treatment of sacroiliac joint pain is best performed in the context of a multidisciplinary approach. Conservative treatments address the underlying causes (posture and gait disturbances) and consist of exercise therapy and manipulation. Intra-articular sacroiliac joint infiltrations with local anesthetic and corticosteroids hold the highest evidence rating (1 B+). If the latter fail or produce only short-term effects, cooled radiofrequency treatment of the lateral branches of S1 to S3 (S4) is recommended (2 B+) if available. When this procedure cannot be used, (pulsed) radiofrequency procedures targeted at L5 dorsal ramus and lateral branches of S1 to S3 may be considered (2 C+). ■

Address correspondence and reprint requests to: Pascal Vanelderden, MD, FIPP, Multidisciplinary Pain Centre, Ziekenhuis Oost-Limburg, Stalenstraat 2, 3600 Genk, Belgium. E-mail: pascal.vanelderden@gmail.com.
DOI: 10.1111/j.1533-2500.2010.00394.x

Key Words: evidence-based medicine, low back pain, sacroiliac joint, radiofrequency, cooled radiofrequency treatment

INTRODUCTION

This review on sacroiliac joint (SIJ) pain is part of the series “Evidence-Based Interventional Pain Medicine according to Clinical Diagnoses.” Recommendations formulated in this article are based on “Grading strength of recommendations and quality of evidence in clinical guidelines” described by Guyatt et al.¹ and adapted by van Kleef et al.² in the editorial accompanying the first article of this series (Table 1). The latest literature update was performed in October 2009. Per agreement of the authors, the names of the anatomical structures are noted in Latin.

The SIJ has long been considered an important source of low back pain because of the empirical finding that treatment targeting the SIJ can relieve pain. The International Association for the Study of Pain (IASP) has formulated criteria for the diagnosis of SI joint pain.³ SI joint pain is defined as pain localized in the region of the SI joint, reproducible by stress and provocation tests of the SI joint, and reliably relieved by selective infiltration of the SI joint with a local anesthetic. Depending on the diagnostic criteria employed (clinical examination, intra-articular test blocks, medical imaging), the reported prevalence of SI pain among patients with axial low back pain varies between 16% and 30%.⁴⁻⁶

The SI joint is a diarthrodial synovial joint. Only the anterior part is a true synovial joint. The posterior part is a syndesmosis consisting of the ligamenta sacroiliaca, the musculus gluteus medius and minimus, and the mus-

culus piriformis. The SI joint cannot function independently because all of these muscles are shared with the hip joint. The ligamentous structures and the muscles that they support influence the stability of the SI joint. The SI joint is innervated mainly by the sacral rami dorsales.⁷

SI joint pain can be divided into intra-articular causes (infection, arthritis, spondyloarthropathies, malignancies) and extra-articular causes (enthesopathy, fractures, ligamentous injuries, and myofascia). Frequently, no specific cause can be identified. Unidirectional pelvic shear stress, repetitive torsional forces, and inflammation can all cause pain. Risk factors include leg length discrepancy, abnormal gait pattern, trauma, scoliosis, lumbar fusion surgery with fixation of the sacrum, heavy physical exertion, and pregnancy.⁸⁻¹³ In patients who suffer from persistent low back pain after a technically successful lumbar arthrodesis, a prevalence rate between 32% and 35% has been demonstrated by means of diagnostic intra-articular blocks.¹¹

I. DIAGNOSIS

I.A HISTORY

Pain from the SI joint is generally localized in the gluteal region (94%). Referred pain may also be perceived in the lower lumbar region (72%), groin (14%), upper lumbar region (6%), or abdomen (2%). Pain referred to

Table 1. Summary of Evidence Scores and Implications for Recommendation

Score	Description	Implication
1 A+	Effectiveness demonstrated in various RCTs of good quality. The benefits clearly outweigh risk and burdens	Positive recommendation
1 B+	One RCT or more RCTs with methodologic weaknesses, demonstrate effectiveness. The benefits clearly outweigh risk and burdens	
2 B+	One or more RCTs with methodologic weaknesses, demonstrate effectiveness. Benefits closely balanced with risk and burdens	
2 B±	Multiple RCTs, with methodologic weaknesses, yield contradictory results better or worse than the control treatment. Benefits closely balanced with risk and burdens, or uncertainty in the estimates of benefits, risk and burdens.	Considered, preferably study-related
2 C+	Effectiveness only demonstrated in observational studies. Given that there is no conclusive evidence of the effect, benefits closely balanced with risk and burdens	
0	There is no literature or there are case reports available, but these are insufficient to suggest effectiveness and/or safety. These treatments should only be applied in relation to studies.	Only study-related
2 C-	Observational studies indicate no or too short-lived effectiveness. Given that there is no positive clinical effect, risk and burdens outweigh the benefit	Negative recommendation
2 B-	One or more RCTs with methodologic weaknesses, or large observational studies that do not indicate any superiority to the control treatment. Given that there is no positive clinical effect, risk and burdens outweigh the benefit	
2 A-	RCT of a good quality which does not exhibit any clinical effect. Given that there is no positive clinical effect, risk and burdens outweigh the benefit	

RCT, randomized controlled trial.

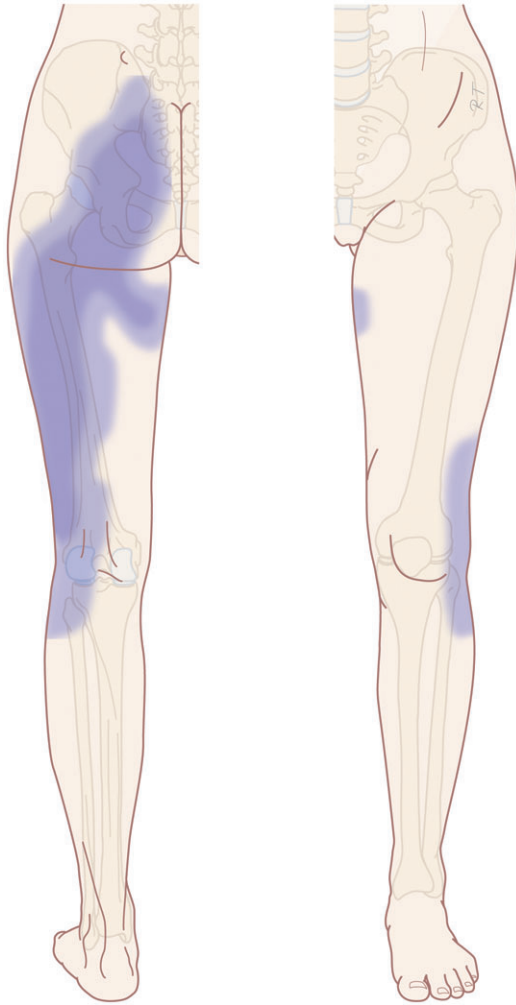


Figure 1. Typical pain referral pattern of sacroiliac joint pain (illustration: Rogier Trompert Medical Art <http://www.medical-art.nl>).

the lower limb occurs in 28% of patients; 12% report pain in the foot¹⁴ (Figure 1).

I.B PHYSICAL EXAMINATION

Solitary provocative maneuvers have little diagnostic value. Because of the size and the immobility of the SI interface, large forces are needed to stress the joint (causing false negatives). In addition, if forces are exerted incorrectly, pain can be provoked in neighboring structures, resulting in false-positive tests. However, both the sensitivity and specificity of the clinical examination increase as a direct function of the number of positive tests. Two studies found that 3 or more positive provocative tests resulted in a specificity and sensitivity of 79% and 85%, and 78% and 94%, respectively.^{15,16} This was

confirmed by a meta-analysis, which showed that 3 or more positive stress tests have discriminative power for diagnosing SI joint pain.¹⁷ Young et al.¹⁸ found a positive correlation between SI joint pain and worsening of symptoms when rising from a sitting position, when symptoms are unilateral, and with 3 positive provocative tests.

The 7 most important clinical tests, which are positive when they reproduce a patient's typical pain, are listed below.

1. Compression test (approximation test): The patient lies on his or her side with the affected side up; the patient's hips are flexed 45°, and the knees are flexed 90°. The examiner stands behind the patient and places both hands on the front side of the iliac crest and then exerts downward, medial pressure.
2. Distraction test (gapping test): The examiner stands on the affected side of the supine patient and places his/her hands on the ipsilateral spinae iliacae anteriores superiores. The examiner then applies pressure in the dorso-lateral direction.
3. Patrick's sign (flexion abduction external rotation test): The patient is positioned supine with the examiner standing next to the affected side. The leg of the affected side is bent at the hip and knee, with the foot positioned under the opposite knee. Downward pressure is then applied to the knee of the affected side.
4. Gaenslen test (pelvic torsion test): The patient lies in a supine position with the affected side on the edge of the examination table. The unaffected leg is bent at both the hip and knee, and maximally flexed until the knee is pushed against the abdomen. The contralateral leg (affected side) is brought into hyperextension, and light pressure is applied to that knee.
5. Thigh thrust test (posterior shear test): The patient lies in the supine position with the unaffected leg extended. The examiner stands next to the affected side and flexes the extremity at the hip to an angle of approximately 90° with slight adduction while applying light pressure to the bent knee.
6. Fortin's finger test: The patient can consistently indicate the location of the pain with 1 finger inferomedially to the spinae iliacae posteriores superiores.
7. Gillet test: The patient stands on one leg and pulls the other leg up to his or her chest.

I.C ADDITIONAL TESTS

Medical imaging is indicated only to rule out so-called “red flags.”¹⁹ In various studies, the use of radiography, computed tomography (CT), single photon emission CT, bone scans, and other nuclear imaging techniques have been used to identify specific disorders of the SI joint. However, no correlation has been consistently demonstrated between the imaging findings and injection-confirmed SI joint pain.²⁰ Magnetic resonance imaging (MRI) does not allow evaluation of normal anatomy. However, in the presence of spondylarthropathy, MRI can detect inflammation and destruction of cartilage despite normal clinical presentation.^{21,22}

Diagnostic Blocks

The IASP criteria mandate that pain should disappear after intra-articular SI joint infiltration with local anesthetic in order to confirm the diagnosis. A number of authors have used a single diagnostic block for clinical studies.^{5,7,14,23} Others advocate confirmatory (double) diagnostic blocks using 2 different local anesthetics containing different durations of action.^{6,15,16,24–27} Yet, the diagnostic value of SI joint infiltration with local anesthetic remains controversial in light of the potential for false-positive and false-negative results. Potential causes of inaccurate blocks include dispersal of the local anesthetic to adjacent pain-generating structures (muscles, ligaments, nerve roots), the overzealous use of superficial anesthesia or sedation, and failure to achieve infiltration throughout the entire SI joint complex. The use of fluoroscopy or other imaging to guide needle placement during SI joint blocks is strongly recommended; in 1 study, only 22% of blind procedures resulted in intra-articular injectate spread.²⁸ CT-monitored injections are useful when the SI joint cannot be accessed using fluoroscopy.²⁹

I.D DIFFERENTIAL DIAGNOSIS

- Spondyloarthropathy (ankylosing spondylitis, reactive arthritis, psoriatic arthritis . . .).
- Lumbar nerve root compression.
- Facetogenic pain.
- Hip pain.
- Endometriosis.
- Myofascial pain.
- Piriformis syndrome.

II. TREATMENT OPTIONS

Treatment of SI joint pain best consists of a multidisciplinary approach and must include conservative (phar-

macological treatment, cognitive-behavioral therapy, manual medicine, exercise therapy and rehabilitation treatment, and, if necessary, psychiatric evaluation) as well as interventional pain management techniques.

II.A CONSERVATIVE MANAGEMENT

The conservative treatments primarily address the underlying cause. In SI joint pain attributed to postural and gait disturbances, exercise therapy and manipulation can reduce pain and improve mobility. However, there are no controlled studies evaluating patients with injection-confirmed SI joint pain.³⁰

Ankylosing spondylitis (M. Bechterew) is an inflammatory rheumatological disorder that affects the vertebral column and the SI joint. Controlled studies have demonstrated analgesic efficacy for immunomodulating agents in ankylosing spondylitis and other spondylarthropathies. However, no conclusions can be drawn with respect to their specific efficacy in SI joint pain.³⁰

II.B INTERVENTIONAL MANAGEMENT

Patients with SI joint pain resistant to conservative treatment are eligible for intra-articular injections or radiofrequency (RF) treatment.

Articular Injections

SI joint injections with local anesthetic and corticosteroids may provide good pain relief for periods of up to 1 year. It is assumed that intra-articular injections would produce better results than peri-articular infiltrations. Yet, peri-articular infiltrations were demonstrated to provide good pain relief in short-term follow-up in 2 double-blind studies,^{26,27} indicating the importance of extra-articular sources of SI pathology.^{31–33} Controlled studies support the assertion that both intra- and extra-articular injections may be beneficial. Luukkainen et al.³² randomized 24 patients to receive either peri-articular corticosteroid with local anesthetic ($n = 13$), or local anesthetic and saline ($n = 11$). One month after the intervention, visual analog scale (VAS) pain scores had decreased significantly in the corticosteroid group compared with the control patients. Maugars et al.³⁴ treated 13 SI joints in 10 patients. Intra-articular corticosteroids were injected into 6 SI joints, while the remaining 7 joints received physiological saline solution. After 1 month, pain reduction of >70% was noted in 5 of the 6 SI joints treated with corticosteroid, whereas no benefit was noted in the placebo group. In all control patients and 2 in the treatment group who had short-term

symptom palliation, a repeat corticosteroid injection was performed. After 1, 3, and 6 months, significant pain reduction was observed in 86%, 62%, and 58% of patients, respectively.

RF Treatment of the SI Joint

The efficacy of RF treatment of the SI joint is illustrated by several prospective observational,^{35,36} retrospective studies^{37–39} and 1 randomized controlled study.⁴⁰ However, the selection criteria, definition of success, and RF parameters (ie, temperature, duration, and location of RF treatment) have varied widely between studies. Gevargez et al.³⁶ performed three 90°C lesions in the ligamentum sacroiliacum posterior and 1 targeting the L5 ramus dorsalis. In contrast, Ferrante et al.³⁷ performed multiple bipolar intra-articular lesions at 90°C. Cohen and Abdi³⁸ performed single 80°C lesions at the level of the L4–L5 rami dorsales and the S1 to S3 (or S4) rami laterals of the rami dorsales. Yin et al.³⁹ applied a similar technique, except that they excluded the L4 ramus dorsalis, and selected more caudal levels based on concordant sensory stimulation. Burnham and Yasui³⁵ performed bipolar RF strip lesions lateral to the foramen sacrale posterius and a monopolar RF treatment at the level the L5 ramus dorsalis. More recently, Cohen et al.⁴¹ investigated which demographic and clinical variables could be used to predict SI joint RF treatment outcome. In multivariate analysis, pre-procedure pain intensity, age 65 years or older, and pain referral below the knee were all statistically significant predictors of failure.

One study reported the use of pulsed RF (PRF) therapy for the treatment of SI joint pain.⁴² The L4, L5 rami mediales, and the S1, S2 rami laterales of the rami dorsales were the targets of the therapy. Evidence of a good or excellent result (>50% and 80% reduction in the VAS, respectively) was obtained in 73% of the patients. The duration of the clinical effect varied from 6 weeks to 32 weeks.

Because of variable and extensive innervation of the dorsal SI joint, targeting the nerves innervating the joint with “classic” RF methods is sometimes difficult. In 2 double-blind randomized, controlled studies, Dreyfuss et al.^{43,44} demonstrated the superiority of multisite, multi-depth sacral lateral branch blocks over single-site, single-depth blocks to anesthetize the SIJ ligaments. However, these studies also demonstrated that lateral branch blocks do not reliably interrupt nociceptive information emanating from the intra-articular portion of the SI joint complex (ie, capsular

distension). To circumvent anatomical variations in innervations, some investigators have employed internally cooled RF electrodes, which increase the ablative area by minimizing the effect of tissue charring to limit lesion expansion. In 2008, a retrospective case series⁴⁵ and a randomized controlled trial⁴⁰ concerning cooled RF treatment of the SI joint were published. In the retrospective trial 3 to 4 months post-treatment, a mean VAS pain score improvement of 2.9 points was noted (7.1 to 4.2).⁴⁵ Eighteen patients rated their improvement in pain as either improved or much improved, while 8 reported minimal or no improvement. Cohen et al.⁴⁰ performed a randomized placebo-controlled study in which a “classic” RF procedure was performed on the L4 and L5 dorsal branches, and a cooled RF treatment of the S1 to S3 lateral branches. One, 3, and 6 months post-treatment, 79%, 64%, and 57% of patients reported ≥50% pain relief, respectively. In the placebo group, only 14% experienced significant improvement at 1 month follow-up, and none experienced significant benefit 3 months post-procedure. The additional cost of disposable components needed for a cooled RF procedure should be taken into consideration, because in some countries, no reimbursement exists for this procedure.

II.C COMPLICATIONS OF INTERVENTIONAL MANAGEMENT

Although potential complications of articular injections and RF procedures include infection, hematoma formation, neural damage, trauma to the sciatic nerve, gas and vascular particulate embolism, weakness secondary to extra-articular extravasation, and complications related to drug administration, the reported rate of these complications in SI joint treatment is low.⁴⁶

Luukkainen et al.^{31,32} reported no complications from peri-articular SI joint injections. For intra-articular injections, Maugars et al.³⁴ reported only transient perineal anesthesia lasting a few hours and mild sciatica (sciatica) lasting 3 weeks, but no information was given as to the number of patients that reported these side effects.

For RF treatment of the SI joint, Cohen et al.⁴⁰ noted that the majority of 28 patients experienced temporary worsening of pain 5 to 10 days after the procedure that was attributed to procedure-related tissue trauma and temporary neuritis. In a follow-up study, Cohen et al. reported 5 complications out of 77 treated patients.⁴¹ These included 3 cases of temporary paresthesia, 1 superficial skin infection that resolved with antibiotics,

Table 2. Evidence of Interventional Pain Management for SIJ Pain

Technique	Assessment
Therapeutic intra-articular injections with corticosteroids and local anesthetic	1 B+
Radiofrequency (RF) treatment of rami dorsales and laterales	2 C+
Pulsed RF treatment of rami dorsales and rami laterales	2 C+
Cooled RF treatment of the rami laterales	2 B+

SIJ, sacroiliac joint.

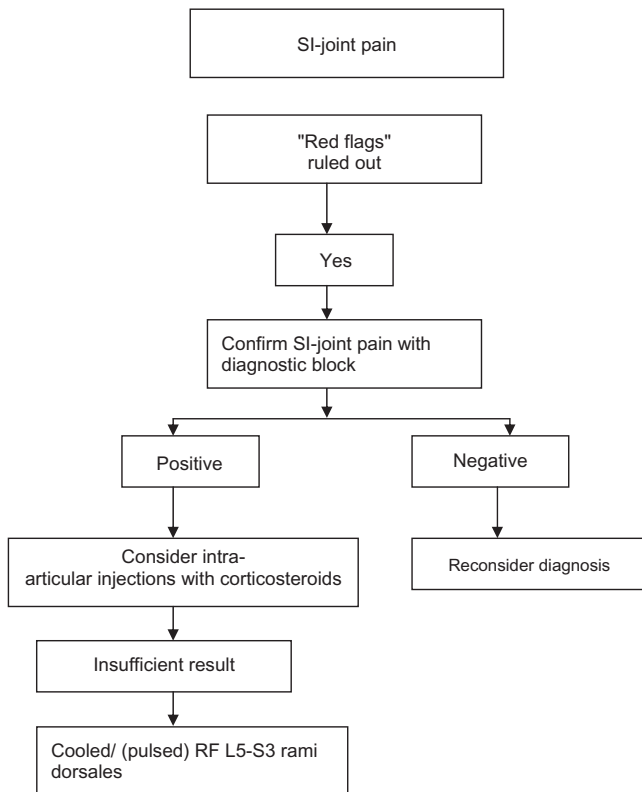


Figure 2. Practice algorithm for treatment of sacroiliac (SI) joint pain. RF, radiofrequency.

and 1 case of hyperglycemia in a diabetic patient requiring increased insulin use for 3 days. The latter was caused by the corticoid used to prevent procedure-related neuritis; this is a relatively common practice that is, however, not supported by improved outcome in the literature. In their study evaluating PRF of the SI joint, Vallejo et al. observed no complications or worsening of pain.^{42,45} Transient buttock dysesthesia or hypoesthesia, and temporary worsening of pain have also been commonly reported in other studies evaluating heat RF.^{35,36,39}

III.D EVIDENCE FOR INTERVENTIONAL MANAGEMENT

A summary of the available evidence for interventional treatment of SIJ pain is given in Table 2.

III. RECOMMENDATIONS

In patients with chronic specific low back complaints possibly originating from the SI joint, an intra-articular injection with a local anesthetic and corticosteroids can be recommended. If the latter fail or produce only short-term effects, cooled RF treatment of the lateral branches of S1 to S3 (S4) is recommended if available. When this procedure cannot be used, (pulsed) RF procedures targeted at L5 dorsal ramus and lateral branches of S1 to S3 may be considered.

III.A CLINICAL PRACTICE ALGORITHM

The practice algorithm is illustrated in Figure 2.

III.B TECHNIQUES

Classical SI Joint Infiltration Technique

- The patient lies in a prone position.
- In anterior-posterior (AP) fluoroscopic projection, the medial SI joint line is formed by the posterior joint articulation.
- Next, the C-arm is rotated contralaterally until the medial cortical line of the posterior articulation is in focus. Tilting the C-arm longitudinally in relation to the patient (cephalo-caudally) can sometimes help the clinician distinguish between the anterior and posterior articulations.
- Skin puncture is 1 to 2 cm cranially from the lower edge of the SI joint at the level of the zone of maximal radiographic translucency.
- Penetration of the SI joint is characterized by a change in resistance. The tip of the needle often appears to be slightly curved between the os sacrum and the os ilium. On a lateral view, the needle tip should appear anterior to the dorsal edge of the sacrum.
- Injection of contrast agent shows dispersal along the articulations and also a filling of the caudal joint capsule. Use only 0.25 to 0.5 mL of contrast agent.
- If this technique is not successful, then approaching the joint from a more rostral puncture point, or using CT, may facilitate penetration.

The needle positioning is illustrated in Figures 3 and 4.

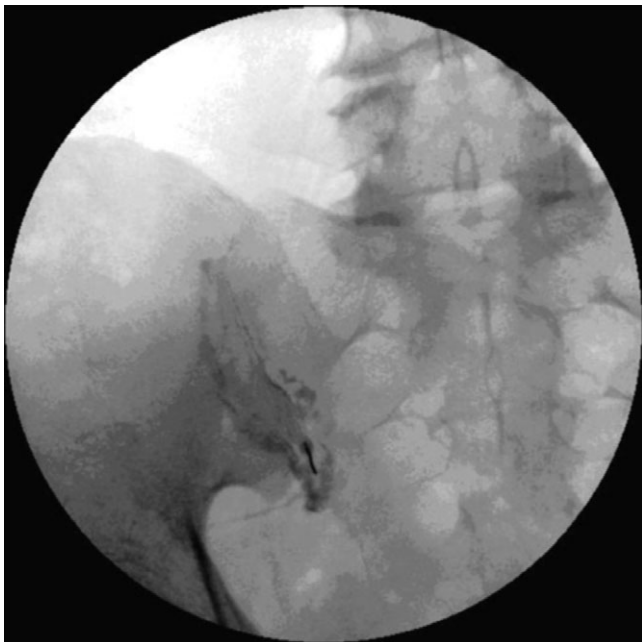

Figure 3. Intra-articular injection of sacroiliac joint with contrast in anterior-posterior view.

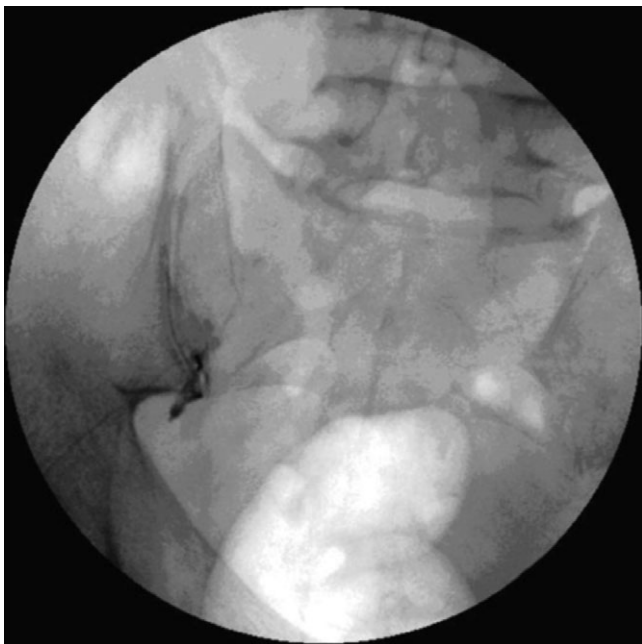

Figure 4. Intra-articular injection of sacroiliac joint with contrast in anterior-posterior view.

RF Treatment Technique of the SI Joint

An RF treatment of the SI joint is performed with fluoroscopic imaging after a positive diagnostic block. The patient is lightly sedated. The C-arm is positioned in

such a way that either a slightly oblique projection (L4 ramus dorsalis), an AP projection (L5 ramus dorsalis and rami laterales), or a cephalo-caudal projection (S1 to S3 rami laterales) is attained. For S1, slight ipsilateral oblique angulation can often increase visualization of the posterior foramen. A 22G SMK-C10 cannula with a 5-mm active tip is inserted until contact is made with the bone at the level of the target nerve. The correct needle position is confirmed with electrostimulation at 50 Hz, at which point paresthesia should be felt in the painful area with thresholds <0.5 V. Right S1 and S2 rami laterales are usually found between “1 o'clock and 5 o'clock” positions on the lateral side of the posterior neuroforamen. For the left S1 and S2 rami laterales, the locations correspond to between “7 o'clock and 11 o'clock.” In view of the small lesion size created by conventional electrodes, and the widespread variability in the location and number of nerves converging on each foramen, multiple lesions may be necessary. Before performing the RF treatment, motor stimulation should be performed to ensure the absence of leg or sphincter contraction. If present, the needle position is incorrect, and repositioning is needed. After correct positioning of the electrode, the RF probe is inserted, and a 90-second RF treatment at 80°C is made.³⁸

Another technique, which has been successfully implemented, targets the S1, S2, and S3 (S4) rami laterales.⁴⁷

Cooled RF of the SI Joint

A cooled RF treatment of the SI joint is performed after a positive diagnostic block. The patient is lightly sedated. C-arm fluoroscopy is used to visualize the sacrum by imaging through the L5/S1 disk space. The L5 ramus dorsales and S1 to S3 rami laterales are targeted. An introducer with stylet is inserted onto the bone endpoint of the posterior sacrum. When inserted, the stylet extends 6 mm beyond the tip of the introducer. The RF probe, which is subsequently inserted via the same introducer, extends only 4 mm beyond the tip of the introducer. To maximize encasement of the lateral branches of the S1 to S3 (S4) nerves, the electrode is placed 8 to 10 mm from the lateral edge of the posterior sacral foramina, with the tip positioned approximately 2 mm proximal to the surface (because of the 2 mm longer introducer). Two or 3 lesions are created at each sacral level. Typically, these lesions are spaced about 1 cm apart from one another, creating a continuous strip of ablated tissue lateral to each foramen. RF energy is

delivered for 2 minutes (30 seconds per lesion) with a target electrode temperature of 60°C. The dorsal branch of the L5 nerve is targeted in a classical manner.

IV. SUMMARY

The SI joint is responsible for 16% to 30% of axial low back complaints and can be difficult to distinguish from other forms of low back pain. Clinical examination and radiological imaging is of limited diagnostic value. The result of diagnostic blocks must be interpreted with caution, because false-positive as well as false-negative results occur frequently. Currently, the majority of scientific evidence points toward intra-articular SI joint infiltrations for short-term improvement. If the latter fail or produce only short-term effects, cooled RF treatment of the lateral branches of S1 to S3 (S4) is recommended (2 B+) if available. When this procedure cannot be used, (pulsed) RF procedures targeted at L5 dorsal ramus and lateral branches of S1 to S3 may be considered (2 C+).

ACKNOWLEDGEMENTS

This review was initially based on practice guidelines written by Dutch and Flemish (Belgian) experts that are assembled in a handbook for the Dutch-speaking pain physicians. After translation, the article was updated and edited in cooperation with U.S./international pain specialists.

The authors thank José Geurts and Nicole Van den Hecke for coordination and suggestions regarding the article.

REFERENCES

- Guyatt G, Gutterman D, Baumann MH, et al. Grading strength of recommendations and quality of evidence in clinical guidelines: report from an American College of Chest Physicians Task Force. *Chest*. 2006;129:174–181.
- van Kleef M, Mekhail N, van Zundert J. Evidence-based guidelines for interventional pain medicine according to clinical diagnoses. *Pain Pract*. 2009;9:247–251.
- Merskey H, Bogduk N. *Classification of Chronic Pain: Descriptions of Chronic Pain Syndromes and Definitions of Pain Terms*. 2nd ed. Seattle, WA: IASP Press; 1994.
- Bernard TN Jr, Kirkaldy-Willis WH. Recognizing specific characteristics of nonspecific low back pain. *Clin Orthop Relat Res*. 1987;266–280.
- Schwarzer AC, Aprill CN, Bogduk N. The sacroiliac joint in chronic low back pain. *Spine*. 1995;20:31–37.
- Maigne JY, Aivaliklis A, Pfefer F. Results of sacroiliac joint double block and value of sacroiliac pain provocation tests in 54 patients with low back pain. *Spine*. 1996;21:1889–1892.
- Fortin JD, Kissling RO, O'Connor BL, Vilensky JA. Sacroiliac joint innervation and pain. *Am J Orthop*. 1999;28:687–690.
- Schuit D, McPoil TG, Mulesa P. Incidence of sacroiliac joint malalignment in leg length discrepancies. *J Am Podiatr Med Assoc*. 1989;79:380–383.
- Herzog W, Conway PJ. Gait analysis of sacroiliac joint patients. *J Manipulative Physiol Ther*. 1994;17:124–127.
- Schoenberger M, Hellmich K. Sacroiliac dislocation and scoliosis. *Hippokrates*. 1964;476–479.
- Katz V, Schofferman J, Reynolds J. The sacroiliac joint: a potential cause of pain after lumbar fusion to the sacrum. *J Spinal Disord Tech*. 2003;16:96–99.
- Marymont JV, Lynch MA, Henning CE. Exercise-related stress reaction of the sacroiliac joint. An unusual cause of low back pain in athletes. *Am J Sports Med*. 1986;14:320–323.
- Albert H, Godsken M, Westergaard J. Prognosis in four syndromes of pregnancy-related pelvic pain. *Acta Obstet Gynecol Scand*. 2001;80:505–510.
- Slipman CW, Jackson HB, Lipetz JS, et al. Sacroiliac joint pain referral zones. *Arch Phys Med Rehabil*. 2000;81:334–338.
- Laslett M, Aprill CN, McDonald B, Young SB. Diagnosis of sacroiliac joint pain: validity of individual provocation tests and composites of tests. *Man Ther*. 2005;10:207–218.
- van der Wurff P, Buijs EJ, Groen GJ. A multitest regimen of pain provocation tests as an aid to reduce unnecessary minimally invasive sacroiliac joint procedures. *Arch Phys Med Rehabil*. 2006;87:10–14.
- Szadek KM, van der Wurff P, van Tulder MW, Zuurmond WW, Perez RS. Diagnostic validity of criteria for sacroiliac joint pain: a systematic review. *J Pain*. 2009;10:354–368.
- Young S, Aprill C, Laslett M. Correlation of clinical examination characteristics with three sources of chronic low back pain. *Spine J*. 2003;3:460–465.
- Bigos S, Bowyer O, Braen G, et al. Acute low back pain problems in adults. Clinical Practice Guideline No. 14. AHCPR Publication No. 95-0642. Rockville, MD: Agency for Healthcare Policy and Research, Public Health Service, U.S. Department of Health and Human Services; December 1994.
- Hansen HC, McKenzie-Brown AM, Cohen SP, et al. Sacroiliac joint interventions: a systematic review. *Pain Physician*. 2007;10:165–184.
- Puhakka KB, Jurik AG, Schiottz-Christensen B, et al. MRI abnormalities of sacroiliac joints in early spondylarthropathy: a 1-year follow-up study. *Scand J Rheumatol*. 2004;33:332–338.

22. Puhakka KB, Melsen F, Jurik AG, et al. MR imaging of the normal sacroiliac joint with correlation to histology. *Skeletal Radiol.* 2004;33:15–28.
23. Dreyfuss MD. Practice guidelines and protocols for sacroiliac joint blocks. In: International Spine Intervention Society, ed. *ISIS 9th Annual Scientific Meeting*. San Francisco, CA: ISIS; 2001:35–49.
24. Laslett M, Young SB, Aprill CN, McDonald B. Diagnosing painful sacroiliac joints: a validity study of a McKenzie evaluation and sacroiliac provocation tests. *Aust J Physiother.* 2003;49:89–97.
25. Maigne JY, Boulahdour H, Chatellier G. Value of quantitative radionuclide bone scanning in the diagnosis of sacroiliac joint syndrome in 32 patients with low back pain. *Eur Spine J.* 1998;7:328–331.
26. Manchikanti L, Singh V, Pampati V, et al. Evaluation of the relative contributions of various structures in chronic low back pain. *Pain Physician.* 2001;4:308–316.
27. van der Wurff P, Buijs EJ, Groen GJ. Intensity mapping of pain referral areas in sacroiliac joint pain patients. *J Manipulative Physiol Ther.* 2006;29:190–195.
28. Rosenberg JM, Quint TJ, de Rosayro AM. Computerized tomographic localization of clinically-guided sacroiliac joint injections. *Clin J Pain.* 2000;16:18–21.
29. Bollow M, Braun J, Taupitz M, et al. CT-guided intraarticular corticosteroid injection into the sacroiliac joints in patients with spondyloarthropathy: indication and follow-up with contrast-enhanced MRI. *J Comput Assist Tomogr.* 1996;20:512–521.
30. Cohen SP. Sacroiliac joint pain: a comprehensive review of anatomy, diagnosis, and treatment. *Anesth Analg.* 2005;101:1440–1453.
31. Luukkainen R, Nissila M, Asikainen E, et al. Periarticular corticosteroid treatment of the sacroiliac joint in patients with seronegative spondylarthropathy. *Clin Exp Rheumatol.* 1999;17:88–90.
32. Luukkainen RK, Wennerstrand PV, Kautiainen HH, Sanila MT, Asikainen EL. Efficacy of periarticular corticosteroid treatment of the sacroiliac joint in non-spondylarthropathic patients with chronic low back pain in the region of the sacroiliac joint. *Clin Exp Rheumatol.* 2002;20:52–54.
33. Borowsky CD, Fagen G. Sources of sacroiliac region pain: insights gained from a study comparing standard intra-articular injection with a technique combining intra- and peri-articular injection. *Arch Phys Med Rehabil.* 2008;89:2048–2056.
34. Mougars Y, Mathis C, Berthelot JM, Charlier C, Prost A. Assessment of the efficacy of sacroiliac corticosteroid injections in spondylarthropathies: a double-blind study. *Br J Rheumatol.* 1996;35:767–770.
35. Burnham RS, Yasui Y. An alternate method of radiofrequency neurotomy of the sacroiliac joint: a pilot study of the effect on pain, function, and satisfaction. *Reg Anesth Pain Med.* 2007;32:12–19.
36. Gevargez A, Groenemeyer D, Schirp S, Braun M. CT-guided percutaneous radiofrequency denervation of the sacroiliac joint. *Eur Radiol.* 2002;12:1360–1365.
37. Ferrante FM, King LF, Rochè EA, et al. Radiofrequency sacroiliac joint denervation for sacroiliac syndrome. *Reg Anesth Pain Med.* 2001;26:137–142.
38. Cohen SP, Abdi S. Lateral branch blocks as a treatment for sacroiliac joint pain: a pilot study. *Reg Anesth Pain Med.* 2003;28:113–119.
39. Yin W, Willard F, Carreiro J, Dreyfuss P. Sensory stimulation-guided sacroiliac joint radiofrequency neurotomy: technique based on neuroanatomy of the dorsal sacral plexus. *Spine.* 2003;28:2419–2425.
40. Cohen SP, Hurley RW, Buckenmaier CC 3rd, et al. Randomized placebo-controlled study evaluating lateral branch radiofrequency denervation for sacroiliac joint pain. *Anesthesiology.* 2008;109:279–288.
41. Cohen SP, Strassels SA, Kurihara C, et al. Outcome predictors for sacroiliac joint (lateral branch) radiofrequency denervation. *Reg Anesth Pain Med.* 2009;34:206–214.
42. Vallejo R, Benyamin RM, Kramer J, Stanton G, Joseph NJ. Pulsed radiofrequency denervation for the treatment of sacroiliac joint syndrome. *Pain Med.* 2006;7:429–434.
43. Dreyfuss P, Snyder BD, Park K, et al. The ability of single site, single depth sacral lateral branch blocks to anesthetize the sacroiliac joint complex. *Pain Med.* 2008;9:844–850.
44. Dreyfuss P, Henning T, Malladi N, Goldstein B, Bogduk N. The ability of multi-site, multi-depth sacral lateral branch blocks to anesthetize the sacroiliac joint complex. *Pain Med.* 2009;10:679–688.
45. Kapural L, Nageeb F, Kapural M, et al. Cooled radiofrequency system for the treatment of chronic pain from sacroiliitis: the first case-series. *Pain Pract.* 2008;8:348–354.
46. Manchikanti L, Boswell MV, Singh V, et al. Comprehensive evidence-based guidelines for interventional techniques in the management of chronic spinal pain. *Pain Physician.* 2009;12:699–802.
47. Buijs EJ, Kamphuis E, Groen GJ. Radiofrequency treatment of sacroiliac joint-related pain aimed at the first three sacral dorsal rami: a minimal approach. *Pain Clin.* 2004;16:139–146.